

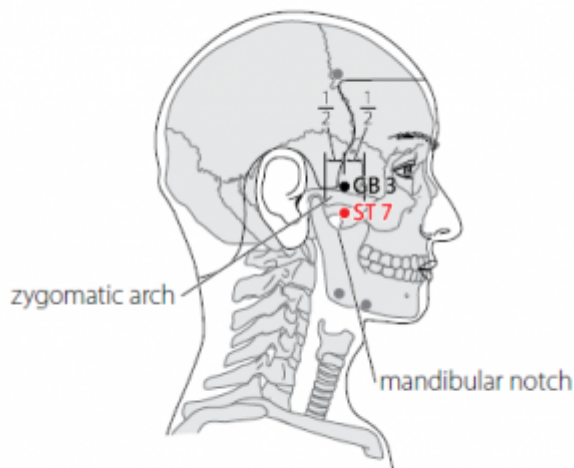
Table des matières

1. Dénomination	1
1.1. Traduction	1
1.2. Origine	1
1.3. Explication du nom	2
1.4. Noms secondaires	2
1.5. Autres Romanisations et langues asiatiques	2
1.6. Code alphanumérique	2
2. Localisation	2
2.1. Textes modernes	2
2.2. Textes classiques	3
2.3. Rapports et coupes anatomiques	3
2.4. Rapports ponctuels	9
3. Classes et fonctions	9
3.1. Classe ponctuelle	9
3.2. Classe thérapeutique	10
4. Techniques de stimulation	10
5. Indications	10
5.1. Littérature moderne	11
5.2. Littérature ancienne	11
5.3. Associations	11
5.4. Revues des indications	12
Études cliniques et expérimentales	12
6.1. Rhinite allergique	12
6.2. Paralysie faciale	12
6.3. Névralgie faciale	12
6.4. Sciatique	14
6.5. Talalgie	14
6.6. Algies plantaires	14
6.7. Dysfonction de l'articulation temporo-mandibulaire	14

7E Xiaguan 下关[下關]

prononciation  [xiaguan.mp3](#)

articles connexes: - 6E - 8E - [Méridien](#) -



 WHO 2009

1. Dénomination

1.1. Traduction

下关 xià guān	Barrière inférieure (Nguyen Van Nghi 1971) Au-dessous de la barre ou Plus bas que le mécanisme (Pan 1993) Charnière inférieure (Lade 1994) Au-dessous de la barrière (Laurent 2000)
-----------------------	--

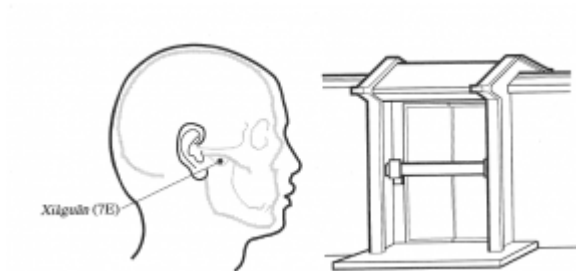
- Zhou Mei-sheng 1984 : *xia* lower; below *guan* joint
- *Xia* (Ricci 1837) : le bas, le dessous, inférieur, en bas ; descendre, abaisser (Guillaume 1995). *Xia* inférieur, au-dessous... Cf. 8GI *xialian* (Laurent 2000).
- *Guan* (Ricci 2788) : barre de bois servant à fermer la porte, barrière (Guillaume 1995). *Guan* action de tisser, les deux fils figurent les fils de la chaîne, les traits inférieurs figurent la navette qui passe et repasse faisant la trame. Recatégorisé par la porte *men* 門 (K 169). *Guan* représente la barre que l'on glisse le long des deux battants pour interdire l'entrée, d'où les sens :barrière ;fermer, clore, boucher ; poste frontière, passe, défilé, passage ;clé, pièce essentielle d'un mécanisme ;en médecine chinoise : organes vitaux, parfois organes des sens ; mettre en rapport (Laurent 2000).

1.2. Origine

- Ling shu, chapitre « Ben shu » (Guillaume 1995).

1.3. Explication du nom

- Zhou Mei-sheng 1984 : *Xiaguan* The point is below the joint of the jaw and the zygomatic arch.
- Pan 1993 : Il se trouve « Au-dessous de la barre » (représentée par l'arcade zygomatique) ou « Plus bas que le mécanisme » (de l'articulation de la mâchoire).



Jiguan (7E) : Au-dessous de la barre. La « barre » correspond à l'arcade zygomatique.
Guan — longue pièce de bois qui sert à barrer une porte par l'intérieur (Pan 1993).

Lade 1994 : le nom fait référence à la localisation anatomique du point et à sa zone d'influence sur l'articulation temporo-mandibulaire.

- Laurent 2000 : *guan* est ici l'arcade zygomatique, cette zone anatomique se nomme également *yaguan* (barrière des dents), *xia* qui signifie au-dessous, inférieur se rapporte à la situation du point, de manière à le distinguer du point de VB situé au-dessus de l'arcade et qui lui se nommera *shangguan* : au-dessus de la barrière.

1.4. Noms secondaires

1.5. Autres Romanisations et langues asiatiques

- cha koann, sia koann (fra.)
- Hsia Kuan (eng.)
- Ha Quan (viet.)
- ha gwan (cor.)
- ge kan (jap.)

1.6. Code alphanumérique

- ES7, 7E (Estomac)
- ST 7 (Stomach)

2. Localisation

2.1. Textes modernes

- Nguyen Van Nghi 1971 : En avant de l'oreille, au-dessous du zygoma, dans un creux qui se

forme lorsqu'on ouvre la bouche.

- Roustan 1979 : la bouche étant fermée, dans la dépression située au bord inférieur de l'arcade zygomatique, en avant de l'articulation temporo-mandibulaire.
- Deng 1993 : sur la face, en avant de l'oreille, dans la dépression qui se forme entre l'arcade zygomatique et la saillie du condyle du maxillaire inférieur.
- Pan 1993 : *Xiaguan* est situé en avant de l'articulation temporo-mandibulaire, au-dessous de l'arcade zygomatique.
- Lade 1994 : quand la bouche est légèrement ouverte, le point est situé dans la dépression au bord inférieur de l'arcade zygomatique, en avant du processus condylien.
- Guillaume 1995 : La bouche fermée, ce point est situé dans la dépression qui se forme sous l'arcade zygomatique, en avant du condyle de la mandibule.
- Laurent 2000 : Sur la face, à 1 travers de doigt en avant du tragus, dans le creux situé sous l'arcade zygomatique, en avant du condyle maxillaire.
- WHO 2009 : On the face, in the depression between the midpoint of the inferior border of the zygomatic arch and the mandibular notch. Note: When the mouth is closed, ST7 is located at the depression inferior to the zygomatic arch, directly inferior to GB3.

Items de localisation

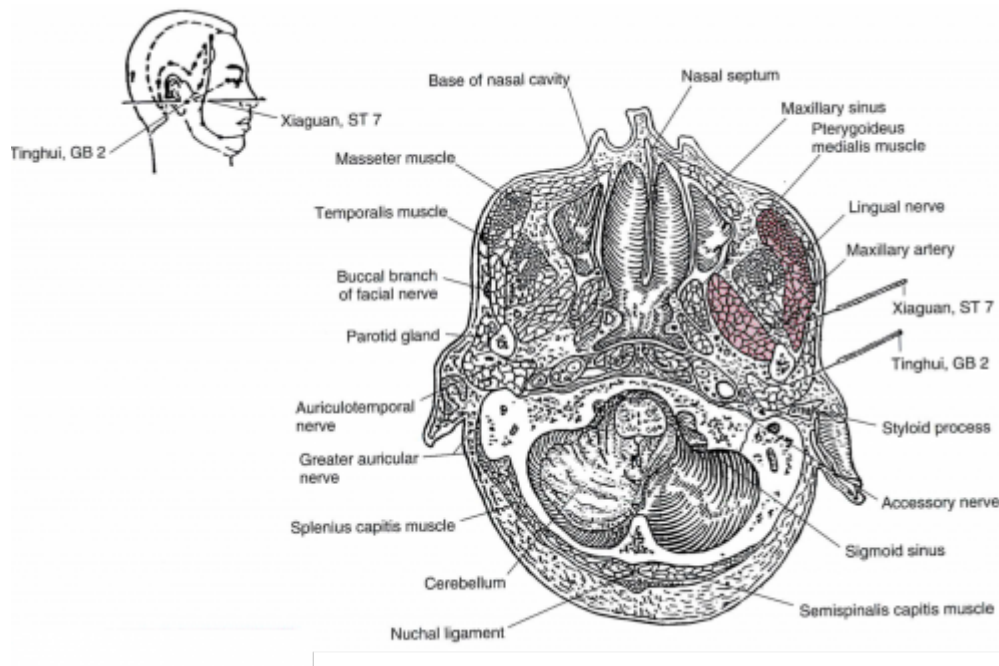
- Oreille
- Zygoma
- Condyle de la mandibule

2.2. Textes classiques

- Jia Yi Jing : Au-dessous de *Shangguan* (3VB), dans la dépression qui se forme au-dessous de l'artère auriculaire antérieure, et qui apparaît quand la bouche se ferme et disparaît quand la bouche s'ouvre (Deng 1993).
- Deng 1993 : Tous les ouvrages de médecine adoptent la localisation figurant dans Jia Yi Jing. Ce point est localisé actuellement dans la dépression qui se forme sous l'arcade zygomatique, en avant du condyle de la mandibule.

2.3. Rapports et coupes anatomiques

- Roustan 1979 : sous la peau, se trouve la glande parotis, en profondeur, le nerf mandibularis, les branches du nerf auriculotemporalis.
- Deng 1993 : Peau—tissu sous-cutané—glande parotide—entre le muscle masséter et l'apophyse zygomatique de l'os temporal—muscle ptérygoïdien externe. Dans la couche superficielle, on trouve les branches du nerf auriculo-temporal, les branches zygomatiques du nerf facial, et l'artère et la veine transverses faciales. Dans la couche profonde, on trouve l'artère et la veine maxillaires, le nerf lingual, le nerf alvéolaire, l'artère méningée moyenne et le plexus ptérygoïdien.
- Guillaume 1995 : Artère faciale. Nerf zygomatique et branche temporale du nerf facial, branches des nerfs auriculo-temporal et mandibulaire.



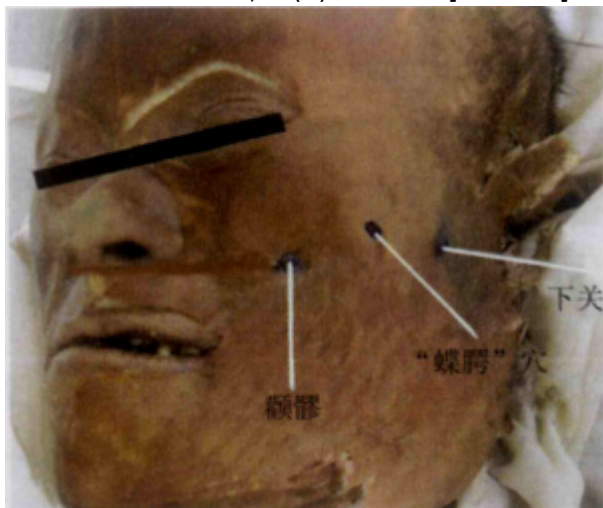Chen 1995.

- Chen 1995 :

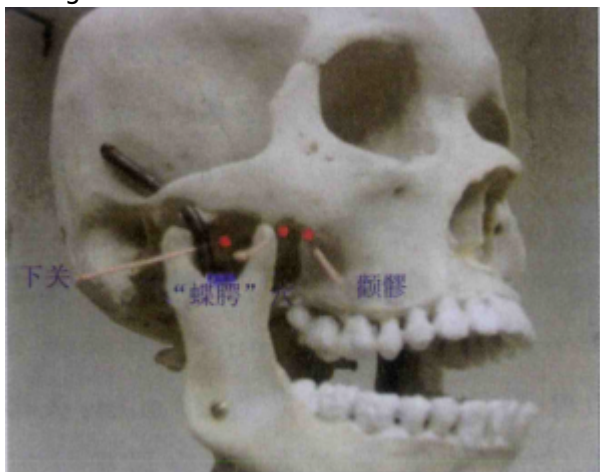
1. Skin: the branches from the auriculotemporal nerve containing fibers from the mandibular division of the trigeminal nerve (CN V) innervate the skin.
2. Subcutaneous tissue: includes the previously described skin nerve branches, the temporal branch of the facial nerve, and the transverse facial artery and vein. The temporal branches containing fibers from the facial nerve (CN VII) innervate the orbicularis oculi, temporal, and levator labii superioris muscles. The transverse artery is a branch of the superficial temporal artery. The transverse facial vein joins the posterior submandibular vein.
3. Parotid gland: the largest salivary gland. The facial ganglion, the auriculotemporal nerve, the superficial temporal artery and vein, and the maxillary artery and vein pass through the parotid gland.
4. Masseter muscle: a rectangular flat muscle. The branches from the masseter nerve containing fibers from the mandibular division of the trigeminal nerve (CN V) innervate the muscle.
5. Posterior temporal muscle and mandibular notch: the branches from the deep temporal nerve containing fibers from the mandibular division of the trigeminal nerve (CN V) innervate the temporal muscle. The mandibular notch is between the carotid process and the condyle of the mandible. The needle is passed posterior to the temporal muscle through the mandibular notch.
6. Maxillary artery and vein: the external carotid artery gives rise to the maxillary artery, and the maxillary vein joins the retromandibular vein.
7. Lateral pterygoid muscle: beneath the infratemporal fossa, a deltoid-shaped muscle. The branches from the lateral pterygoid nerve containing fibers from the mandibular division of the trigeminal nerve (CN V) innervate the muscle.
8. The deepest layer of the needle reaches the mandibular alveolar nerve, the lingual nerve, and the middle meningeal artery. The mandibular alveolar and lingual nerves are the branches of the mandibular division of the trigeminal nerve (CN V). If the needle punctures these structures, soreness and distension of the surrounding region or electrical sensation radiating to the mandibular alveolar will be felt. The middle meningeal artery is a branch of the maxillary artery. To avoid puncturing the needle into the middle meningeal artery, which may cause massive bleeding, don't insert the needle too deeply.

- Wang ZF, Chen Y, Zheng MF, Wu BH, Zhang WG, Lin C, Zhang JD. .[Study on needling depth and

direction from different acupoints to sphenopalatine ganglion]. Chinese Acupuncture and Moxibustion. 2009;29(4):289-92. [154753].



Wang 2009

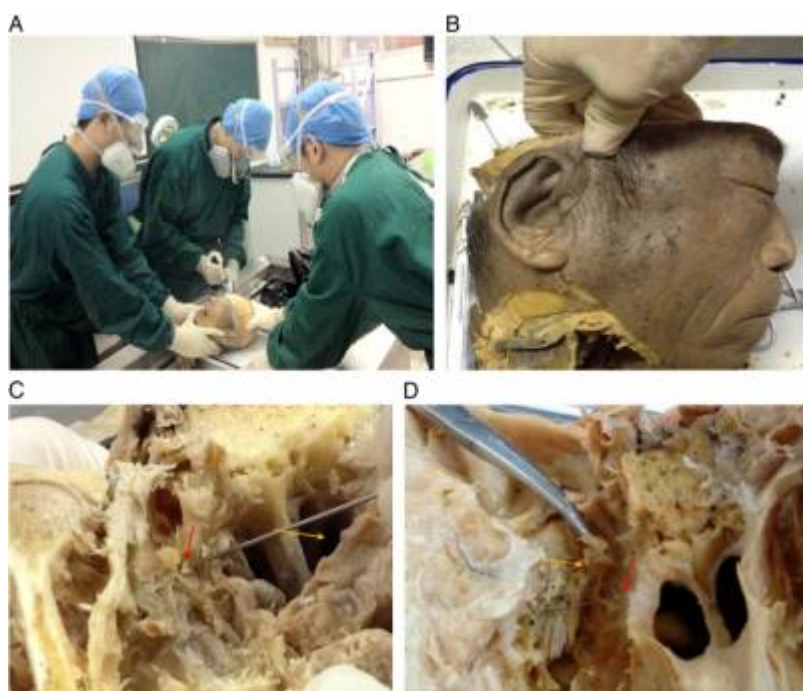

Wang 2009

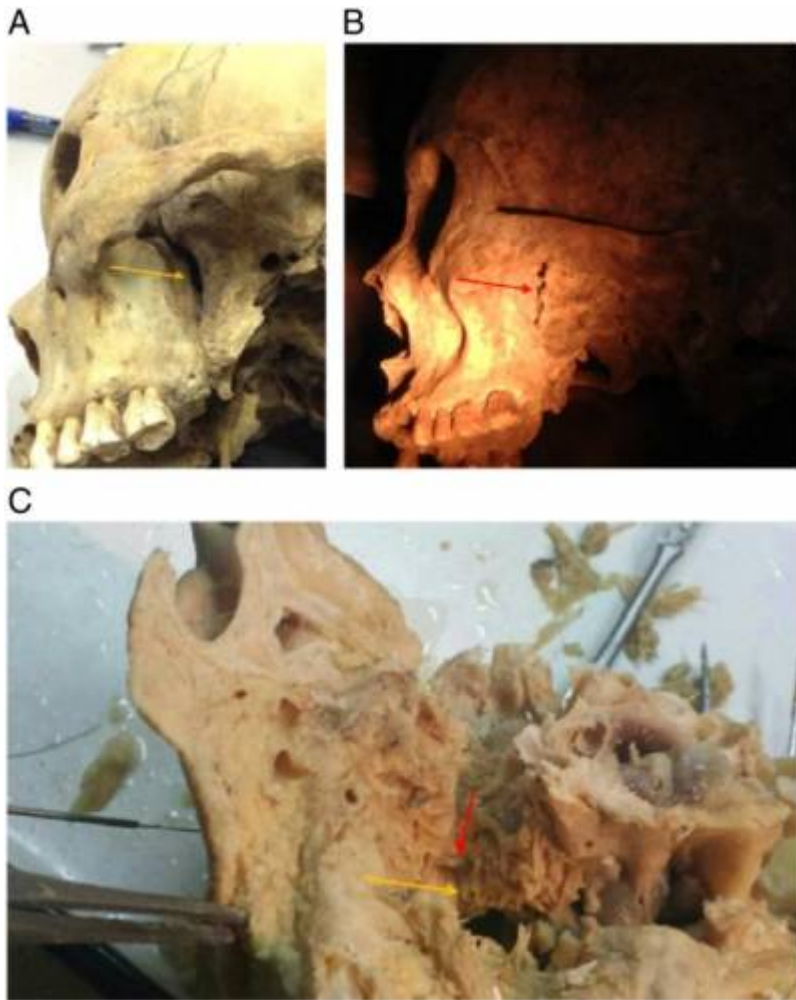
OBJECTIVE: To observe and survey the location of Xiaguan (ST 7), "Die'e" and Quanliao (SI 18) on the surface, and the needling depth and direction from the 3 points to sphenopalatine ganglion. **METHODS:** Fifteen corpses (30 sides) of adult male were fixed by 10% formalin. The lateral areas of face were dissected from the surface to the deep on the 3 acupoints: the electric drill with the kirschner wire punctured towards the sphenopalatine ganglion and extended to the contralateral areas according to different directions of puncturing sphenopalatine ganglion from the 3 acupoints. The corresponding puncturing points of the 3 acupoints were measured by the coordinate location method. **RESULTS:** (1) Surface location: the distance between Quanliao (SI 18) and "Die'e" was 21 mm and the distance between Xiaguan (ST 7) and "Die'e" was 17 mm; (2) Inserting depth of each point to sphenopalatine ganglion: the depths of Xiaguan (ST 7), "Die'e" and Quanliao (SI 18) were 49.9 mm, 46.9 mm and 46.6 mm, respectively; (3) The coordinate location of the corresponding puncturing points: the puncturing direction of Xiaguan (ST 7) was anterointernal upper corresponding to the area of connecting center between contralateral Taiyang (EX-HN 5) and Tongziliao (GB 1), the distance between the corresponding inserting point of Xiaguan (ST 7) and Sizhukong (TE 23) was 17.6 mm; the puncturing direction of "Die'e" point was posterointernal upper, and the horizontal distance from the corresponding puncture point to the zygomatic arch was 33 mm and the vertical distance from the corresponding puncture point to the eyes' outer canthus was 42 mm; the puncturing direction of Quanliao (SI 18) was posterointernal upper and the distance between the corresponding inserting point and the area of contralateral parietal tuber, the distance between the corresponding inserting point of Quanliao (SI 18) and the connecting line of bilateral external acoustic pore was 28 mm, the distance between the corresponding inserting point of Quan-liao (SI 18) and the medial line of the head was 62 mm. **CONCLUSION:** Understanding the surface location, inserting depths and the general puncturing directions of the 3 points can provide basis for puncturing the sphenopalatine ganglion in clinical practice.

- Zhang L, Fang DL, Jiang DW, Gao Y, Shi DZ. Can the sphenopalatine ganglion be reached by an acupuncture needle? *Acupunct Med.* 2017;35(2): 153-55. [195597].

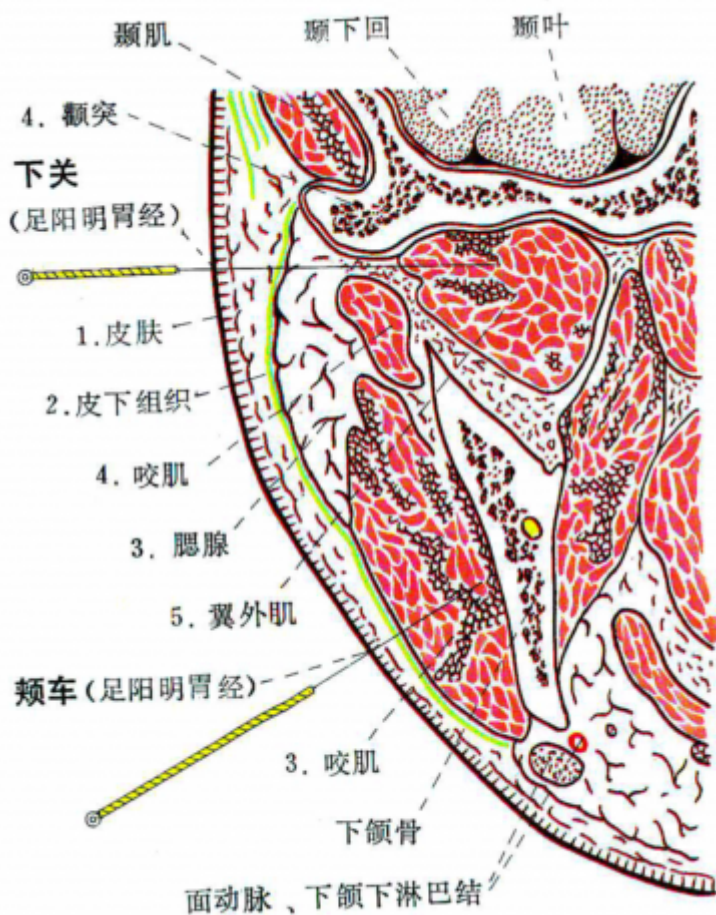
Sphenopalatine ganglion acupuncture was first used for the treatment of rhinitis in the 1960s, and has been widely practised in China since the 1970s.^{1 2} In recent years, this technique has been reported to be effective for rhinitis in clinical practice.³⁻⁵ However, it is challenging to reach the sphenopalatine ganglion with an acupuncture needle. Additionally, the diameters of the arteries in the pterygopalatine fossa are large, and it is possible that the pterygopalatine segment of the maxillary artery could be pierced. In the clinic, it is common for patients to present with lower eyelid bruising the day after treatment, but it is not clear whether this is caused by injury to this vessel. As the sphenopalatine ganglion is relatively small and varies in size between individuals, and given our observations in this study, we believe that inserting the acupuncture needle into the pterygopalatine fossa through the temporal fossa is feasible, when there is no variability in that fossa (figure 2A, B), but that it is actually difficult to reach the sphenopalatine ganglion without visual observation. Previous clinical studies have reported that needles can easily be inserted to touch the sphenopalatine ganglion; however, in this anatomical study, the needle only touched the sphenopalatine ganglion in two of 12 insertions (17%).



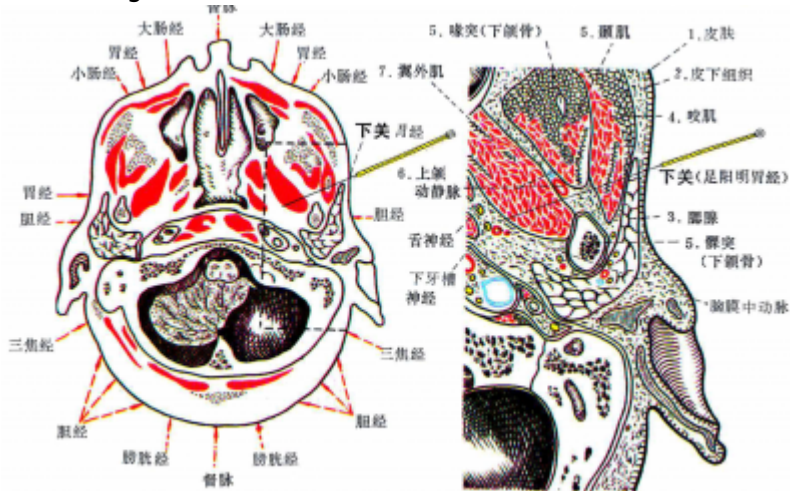
(A) Craniotomy and brain removal. (B) A wet-preserved skull, showing the position of the acupuncture needle. (C) Exposure of the pterygopalatine fossa and sphenopalatine ganglion. After removing tissues along the petrous bone, the pterygoid body was removed to expose the pterygopalatine fossa from behind. The red arrow indicates the sphenopalatine ganglion. The yellow arrow indicates the choanae (marked here to indicate the direction). (D) Acupuncture needle touching the sphenopalatine ganglion (indicated by the red arrow). The yellow arrow indicates lifting of the branches of the trigeminal nerve [Zhang 2017].



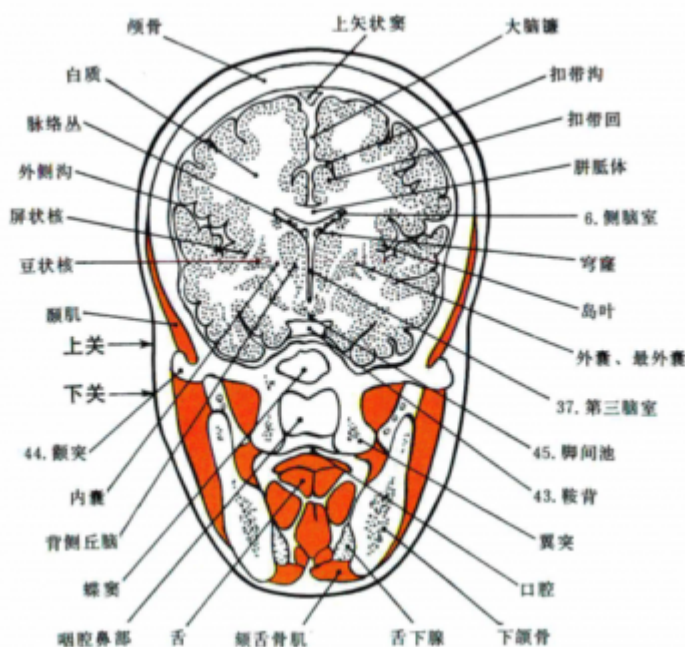
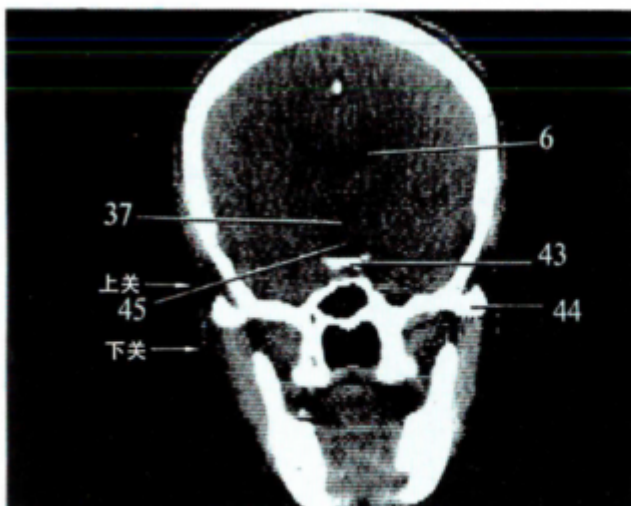(A) Funnel-shaped morphology of the adult pterygomaxillary fissure. The yellow arrow indicates a funnel-shaped adult pterygomaxillary fissure. (B) Jagged morphology of the pterygomaxillary fissure that could affect the acupuncture procedure. The red arrow indicates the jagged adult pterygomaxillary fissure. (C) Needle approaching the pterygopalatine segment of the maxillary artery. The red arrow indicates the needle approaching the pterygopalatine segment of the maxillary artery; the yellow arrow indicates the lumen of the pterygopalatine segment of the maxillary artery [Zhang 2017].



Yan Zhenguo 2002. P 33.



Yan Zhenguo 2002. P 40.



Yan Zhenguo 2002. P 245.

2.4. Rapports ponctuels

3. Classes et fonctions

3.1. Classe ponctuelle

- Guillaume 1995 : Il s'agit d'un point de réunion des méridiens *Zuyangming* et *Zushaoyang*.
- Laurent 2000 : Point de croisement avec *zushaoyang*.

3.2. Classe thérapeutique

- Guillaume 1995 : *Xia Guan* disperse le vent, perméabilise les *Luo*, purifie la chaleur, calme la douleur. Selon le *Tai yi shen zhen*, *Xia guan* disperse le vent et active les *Luo*, ouvre les orifices et stimule le cerveau.
- Laurent 2000 : Élimine la chaleur du *yangming*, traite le condyle maxillaire, améliore les sifflements d'oreille, fait circuler l'énergie du méridien (paralysies faciales).

4. Techniques de stimulation

Acupuncture	Moxibustion	Source
1) Pour les névralgies du trijumeau : diriger l'aiguille vers le bas (A) 2) Pour l'arthrite mandibulaire : piquer obliquement vers l'avant, l'arrière ou le bas à 0,8-1 distance (B) 3) Pour les odontalgies : diriger l'aiguille vers les dents supérieures, la commissure des lèvres ou vers le 6E, à 1,5-2 distances (C) 4) Pour les affections de l'oreille, piquer vers l'arrière, en profondeur à 1,5 distance (D) 5) Pour les spasmes massétéris : piquer vers le bas à une profondeur d'environ 1,5-2 distances (E)		Roustan 1979
Selon Su wen, puncturer à 0,3 distance, laisser l'aiguille le temps de 7 expirations, selon Tong ren, puncturer à 0,4 distance, disperser dès l'obtention du <i>Deqi</i> , ne pas laisser l'aiguille trop longtemps	Selon Su wen appliquer 3 cônes de moxa, selon Tong ren ne pas faire de moxa	Zhen jiu ju ying (Guillaume 1995)
Puncture perpendiculaire entre 0,5 et 1 distance de profondeur	Moxibustion pendant 5 à 10 minutes avec un bâton de moxa	Guillaume 1995
Piquer perpendiculairement de 0,5 à 1 <i>cun</i> . La puncture peut s'effectuer vers l'affection, vers l'avant pour les odontalgies, vers l'arrière pour les pathologies auriculaires, vers le bas pour les spasmes du masséter	Moxas : 1 à 3 ; chauffer légèrement	Laurent 2000

Sensation de puncture

- Roustan 1979: **(A)** : sensation locale de décharge électrique **(B)** : sensation qui diffuse dans toute l'articulation **(C)** : la sensation diffuse dans les dents **(D)** : la sensation diffuse à la région auriculaire **(E)** : sensation de gonflement local

Sécurité

Jia yi jing : « Lorsqu'il y a un bouchon dans l'oreille, il est interdit de faire des moxas » (Guillaume 1995).

5. Indications

Classe d'usage ★★ point majeur

5.1. Littérature moderne

- Nguyen Van Nghi 1971 : Point à puncturer dans les cas de : odontalgie, déviation des yeux et de la bouche, paralysie faciale, surdité, bourdonnement.
- Roustan 1979 : Odontalgies, spasmes du muscle masséter, paralysie faciale, névralgie du trijumeau, otite moyenne, surdité, arthrite mandibulaire. Douleurs des oreilles, luxation de la mâchoire, déviation de la bouche et des yeux.
- Lade 1994 :
 - Disperse le Vent, le Froid et le Vent-Chaleur, et clarifie la Chaleur. Indications : arthrite ou trouble fonctionnel de l'articulation temporo-mandibulaire, névralgie du trijumeau, paralysie faciale, trismus, gingivite et douleurs dentaires.
 - Ouvre les oreilles. Indications : surdité, acouphènes, otite moyenne, et douleurs de l'oreille.
- Guillaume 1995 : Odontalgie, trismus, surdité, bourdonnements d'oreille, otalgie, otites purulentes, déviation de la bouche et des yeux ; arthrite maxillaire inférieure, névralgie faciale, parotidite.

5.2. Littérature ancienne

- Jia yi jing : « Impossibilité d'ouvrir la bouche, caries dentaires inférieures, odontalgies inférieures », « Bourdonnements d'oreille et surdité, déviation de la bouche » (Guillaume 1995).
- Qian Jin yao fang : « Caries et douleurs dentaires », « Otalgies » (Guillaume 1995).
- Wai tai mi yao : « Otites avec écoulement purulent » (Guillaume 1995).
- Ishimpo : Bâillements ; douleur dentaire inférieure ; surdité et bourdonnements d'oreille ; trismus ; douleur de l'arête nasale ; crainte du vent et du froid ; impossibilité de mâcher (Guillaume 1995).
- Tong ren : « Attaque directe par le vent-zhong feng, déviation de la bouche et des yeux, luxation du maxillaire inférieur » (Guillaume 1995).
- Zhen jiu ju ying : impossibilité de bâiller, luxation, temporo-mandibulaire, éblouissements (vertige), odontalgie, vent unilatéral avec déviation de la bouche et de l'œil, bourdonnements d'oreille et surdité, otalgie et otorrhée purulente » (Guillaume 1995).
- Yi xue ru men : « Otalgie, bourdonnements d'oreille, surdité avec écoulement purulent déviation de la bouche, odontalgie du maxillaire inférieur, caries dentaires douloureuses » (Guillaume 1995).
- Da cheng : « Otite avec écoulement purulent, attaque directe par le vent avec paralysie faciale, luxation de la mâchoire inférieure, douleur dentaire avec enflure des gencives. En présence de douleur dentaire avec enflure des gencives, il faut évacuer le sang et le pus à l'aide de l'aiguille triangulaire, puis faire des bains de bouche avec de l'eau salée » (Guillaume 1995).
- Lei jing tu yi : « Hémiplégie-*pian feng* avec déviation de la bouche et de l'œil, surdité, bourdonnements d'oreille, otalgie, prurit de l'oreille et otorrhée purulente, impossibilité de bâiller et luxation temporo-mandibulaire » (Guillaume 1995).
- Tai yi shen zhen : « Hémiplégie avec déviation de la bouche et de l'œil, acouphènes, surdité, otorrhée purulente, otalgie et prurit de l'oreille, odontalgie, luxation de la mâchoire, difficulté à bâiller » (Guillaume 1995).

5.3. Associations

Indication	Association	Source
Arthrite temporo-mandibulaire	7E + 4GI	Roustan 1979

Indication	Association	Source
Arthrite temporale	7E + 19IG + 17TR + 4GI	Shanghai zhen jiu xue (Guillaume 1995)
Spasme massétérin	7E + 17TR + 6E	Roustan 1979
Mâchoires serrées	7E + 6E + 4GI + 5TR	Zhen jiu xue shou ce (Guillaume 1995)
Surdit�	7E + 3TR	Roustan 1979
Surdit�	7E + 21TR + 17TR + 3TR	Shanghai zhen jiu xue (Guillaume 1995)
Bourdonnements d'oreille et surdit�	7E + 5GI + 1TR + 2TR + 5IG	Jia yi jing (Guillaume 1995)
Bourdonnements d'oreille, surdit�, otalgie	7E + 21TR + 19IG + 17TR + 5TR	Zhen jiu xue jian bian (Guillaume 1995)
Caries et douleur dentaires	7E + 5E + 17TR + 12VB	Qian jin (Guillaume 1995)

5.4. Revues des indications

 tudes cliniques et exp rimentales

6.1. Rhinite allergique

- Lu Jinping et al. [Treating 20 Cases of Rhinallergosis by Acupuncture Sphenopalatine Ganglion go through Quanliao Xiaguan]. Journal of Gansu College of TCM. 2000;17(4):30. [89126].

6.2. Paralysie faciale

- Zhu Hongying. [Moxibustion on Points Yifeng and Xiaguan for 186 Cases of Peripheral Facial Paralysis]. Shanghai Journal of Acupuncture and Moxibustion. 1998;17(4):28. [58650].

Moxa-stick moxibustion on points Yifeng (SJ 17) and Xiaguan (ST 7) was applied to 186 cases of peripheral facial paralysis. 166 cases were cured and 20 cases improved, with the curative rate 89% and the total effective rate 100%. It is considered that the shorter the disease course and the earlier the treatment was received, the higher the cure rate and the fewer the sequelae. This therapy is particularly suitable in clinic for the special patients who are pregnant, infantile, old, weak and afraid of acupuncture.

6.3. N vralgie faciale

- Wu Jing-Wei. Xuanli Trough to Shangguan and Xiaguan in Treating Trigeminal Neuralgia. International Journal of Clinical Acupuncture. 1999;10(4):414-15. [71779].

The trigeminal neuralgia in TCM terms is noted as "Triple Yang Channel headache". It appears as paroxysmal or short burning pain around the facial trigeminal nervous distributing area. It is caused by two types of factors: one is due to flaring up of the Stomach-fire or externally catching wind-cold, virus infection, or involvement of gomphiasis and dental caries ; the other is due to tumor pressure, direct stimulation from pathologic change of peridentitis and vascular deformity are also blamed. The " onset may mostly occur before or after middle age, and is more frequent in females.

- Han Zhao-Cheng. Treatment of 32 Cases of Primary Trigeminal Neuralgia by Acupuncture plus Moxibustion with Warming Needle on Xiaguan (St 7). Journal of Acupuncture and Tuina Science.

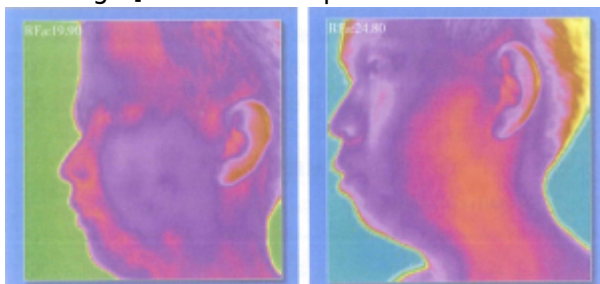
2007;5(4):255. [146924].

The main acupoints of Acupuncture therapy were Xiaguan (ST 7), Sanjian (LI 3), Xiangu (ST 43), Zulinqi (GB 41), Sanyinjiao (SP 6) and Taixi (KI 3). Moxibustion with warming needle on Xiaguan (ST 7), reduction method on Sanjian (LI 3) on the unaffected side and Xiangu (ST 43) and Zulinqi (GB 41) on the affected side, reinforcement method on Sanyinjiao (SP 6) and Taixi (KI 3) on the affected side were given. Moreover, according to the affected area, the local acupoints were added, Yangbai (GB 14) for the ophthalmic branch, Quanliao (SI 18) for the maxillary branch and Jiache (ST 6) for the mandibular branch. Among 32 cases, after 24 acupuncture treatments, 4 cases were cured, 19 cases got marked effectiveness, 7 cases was improved and 2 cases had no effectiveness.

- He L, Zhou WY, Zhang XM. [Trigeminal Neuralgia of Hyperactive of Liver Yang Type treated with Acupuncture at Xiaguan (St 7) at Different Depth: A Randomized Controlled Trial]. Chinese Acupuncture And Moxibustion. 2012;32(2):107-10. [162292].

OBJECTIVE: To observe the differences of therapeutic effect in primary trigeminal neuralgia (PTN) of hyperactive of liver yang type treated by deep and shallow puncturing at Xiaguan (ST 7). METHODS: Sixty-three cases of PTN of hyperactive of liver yang type were randomly divided into a deep puncturing group (32 cases) and a shallow puncturing group (31 cases). Xiaguan (ST 7) of affected region, Hegu (LI 4) and Taichong (LV 3) of bilateral sides, Cuanzhu (BL 2), Sibai (ST 2) and Jiachengjiang (Extra) relevant to the affected branch of nerve stem were selected in both groups. In deep puncturing group, Xiaguan (ST 7) was punctured to the depth of sphenopalatine ganglion (SPG); Cuanzhu (BL 2), Sibai (ST 2) and Jiachengjiang (Extra) were respectively punctured to the depth of supraorbital foramen, infraorbital foramen and mental foramen. In shallow group, routine puncturing was applied; the needles were connected with G6805 electric acupuncture apparatus, and switched on for 30 min every time; the treatment was applied every other day. Pain index, traditional Chinese medicine symptoms index and clinical therapeutic effect were observed after 2 courses of treatment. RESULTS: In deep puncturing group, the VAS scores and the traditional Chinese medicine symptoms scores (pain degree, pain frequency, upsetting, conjunctival congestion, bitter mouth and hypochondriac pain) after treatment were much more lower than those before treatment (all $P < 0.01$); in shallow puncturing group, except hypochondriac pain ($P > 0.05$), other indices above after treatment were obviously lower than those before treatment ($P < 0.01$, $P < 0.05$). Compared with the indices in both groups after treatment, the VAS scores, the pain degree, conjunctival congestion and total scores of traditional Chinese medicine symptoms in deep puncturing group were more significant (all $P < 0.05$). The total effective rate was 93.8% (30/32) in deep puncturing group, superior to that of 87.1% (27/31) in shallow puncturing group ($P < 0.05$). No any adverse reaction was observed in both groups. CONCLUSION: The therapeutic effect of trigeminal neuralgia of hyperactive of liver yang type treated with electroacupuncture is remarkable, and deep puncturing at Xiaguan(ST 7) to SPG is more effective than routine puncturing.

- Fu Y, Zhang HF, Li F, Xiong J, Zhang B, Li L, Chen RX. [Comparative Research of Moxibustion and Infrared Method in Testing Heat-Sensitive State at Xiaguan (St 7) in Primary Trigeminal Neuralgia]. Chinese Acupuncture and Moxibustion. 2013;33(5):411-4. [162550].



Etude thermographique de la moxibustion au 7E dans la névralgie faciale (Fu 2013).

OBJECTIVE: To explore the possibility of the infrared objective displaying of heat-sensitive state of acupoint. METHODS: Fifty-four qualified subjects were enrolled. In the natural state, thermal tomography (TTM) was adopted to shoot the thermograms on the face. After the thermograms collection, the thermo-sensitive detection with moxibustion was applied. The suspending moxibustion with moxa stick was used at Xiaguan (ST 7, affected side) for 10 mm. The cases with heat extension and transmission at the acupoint were

recorded at the end of moxibustion. In following, the second infrared radiation detection was done so as to record the changes in the infrared images on the face before and after moxibustion and compare the difference in the heat-sensitive state at Xiaguan (ST 7, affected side) in the subjects between two detection methods. RESULTS: Before moxibustion, the infrared radiation intensity at Xiaguan (ST 7, affected side) in the patients displayed mostly low temperature feature and its sensibility (true positive rate) was 65.6%, the specificity (true negative rate) was 68.2% and the accuracy was 66.7%. After moxibustion at Xiaguan (ST 7, affected side), there was an obvious block-diffused increment area of infrared radiation along the cheek and its sensitivity (true positive rate) was 81.8%, the specificity (true negative rate) was 81.0% and the accuracy was 81.5% as compared with the moxibustion detection. CONCLUSION: (1) The heat-sensitive state at Xiaguan (ST 7, affected side) in the patients of primary trigeminal neuralgia can be objectively displayed by infrared imaging to a certain extent. (2) The acupoint heat-sensitization produced by moxibustion is not only the subjective sensation of the subjects, but also can be objectively displayed by infrared imaging to a certain extent.

6.4. Sciaticque

- Du X, Zhang Q. [Shu-needling at Xiaguan (ST 7) for 35 cases of primary sciatica]. Zhongguo Zhen Jiu. 2015;35(9):889-90. [181982].

6.5. Talalgie

- Zhao Xishuo. [200 Patients with Painful Heels Treated with Acupuncture on only Xiaguan]. Journal of Clinical Acupuncture and Moxibustion. 2002;18(2):40. [101761].

6.6. Algies plantaires

- Ouyang Qun et al. Acupuncture at upper limb points for pain of the sole : a report of 73 cases. International Journal of Clinical Acupuncture. 1996;7(4):499-501. [56395].

6.7. Dysfonction de l'articulation temporo-mandibulaire

- Yao Min. Treatment of Dysfunction of Temporomandibular Joint with Acupuncture of Xiaguan Point (Abstracts). Acupuncture Research. 2001;26(3):182. [98501].

Dysfunction of temporomandibular joint is one of the common stomatological diseases, marked by discomfort while opening mouth, pain in the temporomandibular joint region and noise appearing while moving the joint. The authors of the present paper treated 17 cases with acupuncture of Xiaguan (ST 7) and got a satisfactory result. Methods: Gauge-30 filiform needle 1.5 cun long was used to insert into Xiaguan (ST 7) rapidly to a depth of about 0.5 cun. The needle was manipulated with uniform reducing-reinforcing method and then retained for 40 minutes. During retention of the needle the focus was irradiated with a TDP lamp. The treatment was given once daily, with 10 treatments being a therapeutic course. For severe patients, Quchi (LI 11) and Hegu (LI 4) were used in combination. Results indicated that after acupuncture treatment all the 17 cases were cured.

From:

<https://ebm.wiki-mtc.org/> - **Encyclopédie des sciences médicales chinoises**

Permanent link:

<https://ebm.wiki-mtc.org/doku.php?id=acupuncture:points:points%20des%20meridiens:estomac:7e> 

Last update: **03 Feb 2022 14:35**